



Royal College of
General Practitioners

nMRCGP

Applied Knowledge Test

50 sample questions

The following 50 questions are in matching, single-best-answer and algorithm formats.

Some of these questions relate to current best practice. They should be answered in relation to published evidence and not according to an individual's local arrangements.

In the live test of three hours duration all 200 items will be used in calculating your score. Marks will not be deducted for incorrect answers; your total score on the test will be the number of correct answers you give. You are therefore advised to attempt all items.

As these are demonstration questions, the answers are intentionally not given.

September 2007

1. *Management of chest pain*

A 55-year-old man has a two hour history of severe central chest pain radiating into his left arm. He has no previous significant medical history. His BP is 150/85, his chest is clear and his pulse is regular 90/min.

In addition to aspirin, which is the SINGLE MOST appropriate NEXT drug for this patient? Select ONE option only.

- A Amiodarone
- B Carvedilol
- C Diamorphine
- D Furosemide
- E Ramipril

2. *Post-myocardial infarction*

A 58-year-old woman attends two months after a myocardial infarct. She has made a good recovery but has developed features of low mood and poor sleep pattern with early morning wakening.

Which is the SINGLE MOST appropriate drug for this patient's current symptoms? Select ONE option only.

- A Amitriptyline
- B Fluoxetine
- C Lofepramine
- D Mirtazapine
- E Venlafaxine

Viruses

A	Adenovirus	F	Herpes simplex virus
B	Cytomegalovirus	G	Human papilloma virus
C	Echovirus	H	Respiratory syncytial virus
D	Epstein-Barr virus	I	Rotavirus
E	Hepatitis B virus	J	Rubella virus

For each of the clinical conditions below, select the SINGLE MOST likely causative virus from the list of options above. Each option may be used once, more than once, or not at all.

3. Hepatocellular carcinoma
4. Warts
5. Conjunctivitis
6. Infectious mononucleosis
7. Infantile gastroenteritis

Risk of hip fracture

A cohort study is conducted to evaluate the relationship between dietary calcium supplementation and the occurrence of hip fractures in post-menopausal women.

The study examines the hip fracture rate in 100 women taking calcium supplements and 100 women taking placebo over three years.

Over the three year period, five women have hip fractures in the calcium group and ten women have hip fractures in the placebo group. The 95% confidence interval is 0.18 to 1.4.

8. In calculating the RISK of a hip fracture in the TREATED group, which is the SINGLE CORRECT answer? Select ONE option only.

- A 0.01
- B 0.05
- C 0.1
- D 0.5
- E 1.0

9. In calculating the RISK RATIO for this study, which is the SINGLE CORRECT answer? Select ONE option only.

- A 0.01
- B 0.05
- C 0.1
- D 0.5
- E 1.0

10. *Child growth*

An eight-month-old baby girl's routine measurements have fallen from the 50th centile growth line to below the 25th centile growth line over the past three months. She has a history of minor respiratory infections and recurrent gastroenteritis.

Which is the SINGLE MOST appropriate INITIAL investigation? Select ONE option only.

- A Chromosome analysis
- B Glucose-6-phosphate dehydrogenase level
- C Jejunal biopsy
- D Sweat test
- E Thyroid function test

11. *Childhood illness*

A seven-year-old girl has recently arrived in the UK from Eastern Europe. She had a throat infection two weeks ago. Since then she has developed a fever and an acute migratory polyarthritis involving the knees, ankles and wrists. Her parents have noticed her legs twitching.

She has a transient erythematous rash, with ring and crescent shaped patches.

Which is the SINGLE MOST likely diagnosis? Select ONE option only.

- A Allergic polyarthritis
- B Juvenile chronic arthritis
- C Lyme disease
- D Parvovirus
- E Rheumatic fever

12. *Epidemiological measures*

A primary care organisation requires information to estimate the typical duration of hospice services required for patients with pancreatic cancer.

Which is the SINGLE MOST appropriate epidemiological measure for the situation described above? Select ONE option only.

- A Case fatality
- B Incidence
- C Median survival
- D Mortality
- E Prevalence

13. *Epidemiological measures*

Which is the SINGLE MOST appropriate epidemiological measure to estimate the rate at which the new cases of papilloma virus infection occur among students on a college campus? Select ONE option only.

- A Case fatality
- B Incidence
- C Median survival
- D Mortality
- E Prevalence

14. *Weakness*

A 35-year-old woman, who is a sales manager, complains of a six month history of weakness of her forearms and hands particularly in the evening towards the end of her meal. She has recently noticed intermittent double vision. She had a thyroidectomy for thyrotoxicosis five years ago.

Which is the SINGLE MOST likely diagnosis? Select ONE option only.

- A Chronic fatigue syndrome
- B Guillain-Barré syndrome
- C Motor neurone disease
- D Myasthenia gravis
- E Multiple sclerosis

15. *Lethargy*

A 50-year-old man has a six month history of lethargy and impotence. His wife comments that he looks tanned in the winter months. His serum ferritin and iron levels are significantly raised, but his haemoglobin is normal.

Which is the SINGLE MOST likely diagnosis? Select ONE option only.

- A Addison's disease
- B Chronic active hepatitis
- C Diabetes mellitus
- D Haemochromatosis
- E Hypothyroidism

16. Tiredness

A 50-year-old woman, who has recently been diagnosed with hypertension, complains of pain in her knees. She feels tired and her memory is poor. She has lost her appetite recently and feels nauseated most of the time. Urinalysis is normal.

Which is the SINGLE MOST likely diagnosis? Select ONE option only.

- A Chronic fatigue syndrome
- B Chronic renal failure
- C Coeliac disease
- D Cushing's syndrome
- E Hyperparathyroidism

17. *Tiredness*

A 40-year-old woman stopped the combined oral contraceptive pill six months ago because of increased blood pressure. Her periods have not returned, she feels generally tired and has put on weight. A pregnancy test is negative and her fasting blood glucose is 9.2 mmol/L.

Which is the SINGLE MOST likely diagnosis? Select ONE option only.

- A Anaemia
- B Chronic active hepatitis
- C Coeliac disease
- D Cushing's disease
- E Hypothyroidism

18. *Visual disturbance*

A 20-year-old woman notices bright lines of light in both visual fields followed shortly afterwards by a partial loss of her vision. Her visual symptoms resolve after one hour but she has slight nausea.

Which is the SINGLE MOST likely diagnosis? Select ONE option only.

- A Acute glaucoma
- B Migraine
- C Optic neuritis
- D Retinal detachment
- E Vitreous detachment

19. Visual disturbance

A 63-year-old man with poorly controlled hypertension, develops sudden visual loss in his left eye. The visual acuity on the left is reduced to hand movements only. Visual acuity on the right is 6/6. Fundoscopy of the left eye shows flame-shaped retinal haemorrhages spreading out from the disc.

Which is the SINGLE MOST likely diagnosis? Select ONE option only.

- A Acute glaucoma
- B Central retinal artery occlusion
- C Central retinal vein occlusion
- D Retinal detachment
- E Vitreous haemorrhage

Contraceptive advice

- A Two days of extra contraceptive precautions required
- B Seven days of extra contraceptive precautions required
- C 14 days of extra contraceptive precautions required
- D Emergency contraception required
- E No extra precautions required
- F Omit pill free week

For each patient described, select the SINGLE MOST appropriate advice from the list above. Each option may be used once, more than once or not at all

- 20. A 24-year-old woman is taking the combined contraceptive pill. She is on day 19 of the packet and rings to say that she forgot her pill yesterday morning and had intercourse last night. She has taken her pill this morning. Her last period was normal and she has taken all the other pills accurately.
- 21. A 36-year-old woman is taking the progesterone-only pill. She is on day 14 of the packet and rings to say that she forgot her pill yesterday and had intercourse last night. She has taken her pill this morning. Her last period was normal and she has taken all the other pills accurately.
- 22. A 28-year-old woman had her first baby eight weeks ago. She is not breast feeding and wishes to restart contraception straight away. She has not started menstruating yet and receives her first injection of medroxyprogesterone acetate that day.
- 23. A 26-year-old woman is taking the combined contraceptive pill. She forgot to start her new packet of pills three days ago and had intercourse last night. Her last period was normal and she had taken her previous pack of pills accurately.
- 24. A 24-year-old woman is taking the combined contraceptive pill. She is on day six of the packet and is prescribed a seven day course of oral flucloxacillin for a skin infection.

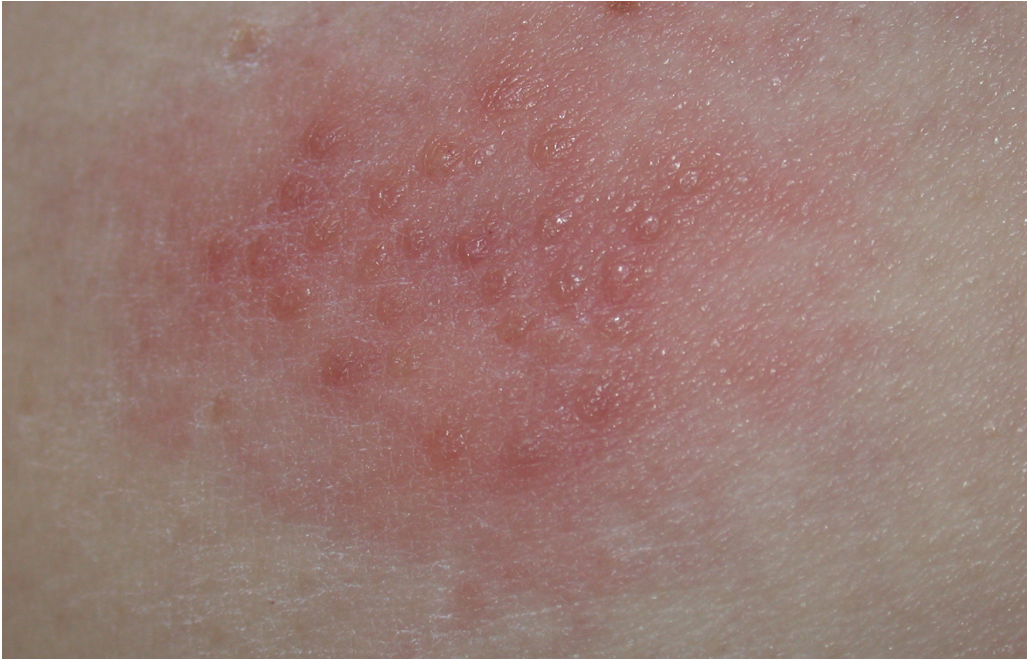25. Medical standards of fitness to drive

A 65-year-old retired man had a routine coronary artery angioplasty and stent insertion one week ago. He is now well and asymptomatic. He asks you for advice about driving.

According to DVLA guidance, which is the SINGLE MOST appropriate advice with regard to driving? Select ONE option only.

- A He may resume drive immediately
- B He may resume driving after a further week
- C He may resume driving one month after the angioplasty
- D He may resume driving six months after the angioplasty
- E He must inform the DVLA and await their decision before resuming driving

26. *Skin rash*

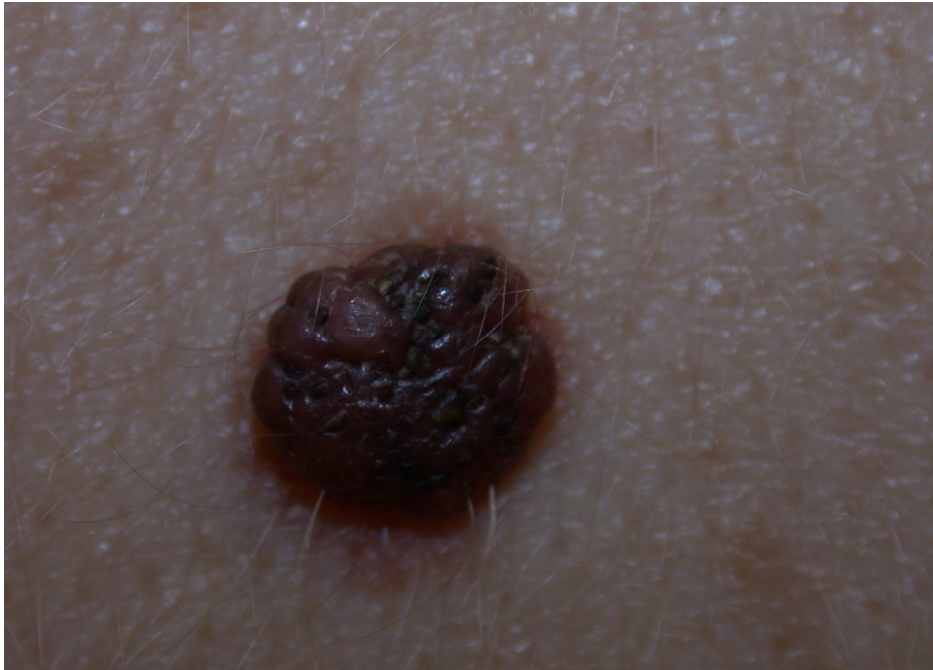

A 34-year-old woman has developed this skin rash on her buttock over the past two days. It is sore to touch and she has no rash elsewhere. She says this has happened on at least three previous occasions and the rash is always in the same place.

Which is the SINGLE MOST likely diagnosis? Select ONE option only.

- A Chickenpox
- B Coxsackie virus infection
- C Dermatitis herpetiformis
- D Herpes simplex
- E Herpes zoster

27. Skin lesion



A 45-year-old man asks you to check this mole which is on his back and catches on his clothing. It has been present for many years and has not changed in appearance

Which is the SINGLE MOST likely diagnosis? Select ONE option only.

- A Benign pigmented naevus
- B Blue naevus
- C Malignant melanoma
- D Pyogenic granuloma
- E Seborrhoeic keratosis

28. *Sickness certification*

You see and examine a patient with back pain who has been off work for seven days. You do not consider that he is fit to return to work yet.

Which is the SINGLE MOST appropriate certificate to issue? Select ONE option only.

- A Med 3
- B Med 4
- C Med 5
- D Med 6
- E RM 7

29. Management of dyspepsia

A 43-year-old woman was diagnosed with a duodenal ulcer at gastroscopy. She has recently completed a course of triple therapy. She comes to see you four weeks post therapy and is symptom free.

Which is the SINGLE MOST appropriate management option? Select ONE option only.

- A Continue proton pump inhibitor for a further one week
- B Check *Helicobacter pylori* serology
- C No follow up needed
- D Refer for barium meal
- E Repeat gastroscopy

30. Rectal pain

For the past week, a 30-year-old woman has noticed a few spots of blood on the toilet paper and experiences sharp pain around the anus when she defecates.

Which is the SINGLE MOST likely diagnosis? Select ONE option only.

- A Anal fissure
- B Haemorrhoids
- C Ischio-rectal abscess
- D Perianal haematoma
- E Rectal carcinoma

31. *Constipation*

An 80-year-old edentulous patient who lives alone and refuses meals on wheels, complains of constipation without rectal bleeding. Her weight is steady, abdominal and rectal examinations are normal and she is otherwise well.

Which is the SINGLE MOST likely diagnosis? Select ONE option only.

- A Alzheimer's disease
- B Carcinoma of the colon
- C Diverticular disease
- D Hypothyroidism
- E Poor fibre intake

32. Adverse drug reaction

A 55-year-old man is diagnosed with hypertension and hyperlipidaemia. Shortly after starting treatment, he develops wheezing at night and on exertion.

**Which is the SINGLE MOST likely drug to have caused these symptoms?
Select ONE option only.**

- A Aspirin
- B Bendroflumethiazide
- C Bezafibrate
- D Enalapril
- E Simvastatin

33. *The investigation of infertility*

A 25-year-old woman has been infertile for three years. She has had recurrent pelvic pain due to endometriosis. Investigations in primary care are reported as follows:

Full blood count – normal
Thyroid function – normal
Sex hormone profile - normal
Rubella serology – immune
Day 21 progesterone – normal
Chlamydia swab – negative

Her partner's semen analysis is reported as normal.

A referral to secondary care is agreed and she asks what is likely to happen next.

According to current guidelines, which is the SINGLE MOST appropriate NEXT investigation? Select ONE option only.

- A Cervical cytology
- B Hysterosalpingogram
- C Hysteroscopy
- D Laparoscopy
- E Post-coital test

Comparison of drug therapies

A pharmaceutical representative provides the following information on 'Wundosporin', a new antifungal treatment for nail infection with *Trichophytum rubrum*, compared with oral terbinafine.

	'Wundosporin' treated group	Terbinafine treated group
Mycologically cured > 12 weeks	40	20
Mycologically not cured > 12 weeks	60	80

34. How many patients took part in the study? Select ONE option only.

- A 20
- B 70
- C 80
- D 100
- E 200

35. Which ONE of the following values is the ABSOLUTE REDUCTION in the risk of persistent infection in the 'Wundosporin' group? Select ONE option only.

- A 20%
- B 40%
- C 50%
- D 60%
- E 100%

36. How many patients would need to be treated with 'Wundosporin' to cure one patient with a fungal nail infection who would not have been cured with terbinafine? Select ONE option only.

- A 1
- B 2
- C 2.5
- D 5
- E 10

37. *The management of patients with abdominal pain*

A 44-year-old man with a history of recurrent gout, develops severe left sided loin pain radiating into his scrotum.

His temperature is 38.3°C. He is tender over the left flank. Urinalysis reveals +++ blood, + nitrite and ++ leucocytes.

**Which is the SINGLE MOST appropriate management option for this man?
Select ONE option only.**

- A Admit immediately to hospital
- B Intramuscular diclofenac
- C Intramuscular pethidine
- D Oral cefadroxil
- E Oral trimethoprim

Causes of double vision

- A Berry aneurysm
- B Cerebral glioma
- C Drug induced
- D Graves' disease
- E Multiple sclerosis
- F Myasthenia gravis
- G Stroke

For each of the patients described, select the SINGLE MOST likely diagnosis from the above list. Select ONE option only.

- 38.** A 27-year-old woman who is a non-smoker, suddenly develops double vision. She had an episode of reduced visual acuity in her left eye whilst on holiday 18 months previously, for which no cause was identified. She has no other significant past medical history.
- 39.** A 35-year-old man who is a non-smoker, suddenly develops a severe headache and double vision. His right pupil is fixed and dilated.
- 40.** A 48-year-old woman has transitory double vision towards the end of most days. She smokes 10 cigarettes/day. She has vitiligo and hypothyroidism.

41. Asthma

An 18-year-old patient with asthma has become increasingly wheezy over the past two days. Her hay fever symptoms are also worse than usual. After a salbutamol nebuliser, her peak flow rate increases from 250 to 450 L/minute and she feels much better.

Which is the SINGLE MOST appropriate next management step? Select ONE option only.

- A Continue usual maintenance inhaler regime
- B Nebulised salbutamol as required
- C Oral amoxicillin
- D Oral chlorphenamine
- E Oral prednisolone

42. Medroxyprogesterone acetate as a parenteral contraceptive

Which **ONE** of the following is an **ABSOLUTE** contraindication to the use of medroxyprogesterone acetate as a contraceptive? Select **ONE** option only.

- A Diabetes mellitus
- B Past history of ovarian cysts
- C Previous ectopic pregnancy
- D Smoking
- E Trophoblastic disease

43. Breast disease

A 28-year-old woman has asymmetric nodularity of the right breast. Her mother and aunt have been treated for breast cancer.

According to the NHS Breast Screening Referral Guidelines, which is the SINGLE MOST appropriate NEXT management option? Select ONE option only

- A Arrange mammography
- B Reassure
- C Refer routinely to breast clinic
- D Refer urgently to breast clinic
- E Review in six weeks

44. Study design

A research study is proposed to reach a summary conclusion regarding the results of several investigations of exposure to environmental tobacco smoke and risk of lung cancer.

Which is the SINGLE MOST appropriate study design? Select ONE option only.

- A Case control study
- B Cohort study
- C Correlation study
- D Descriptive study
- E Meta-analysis

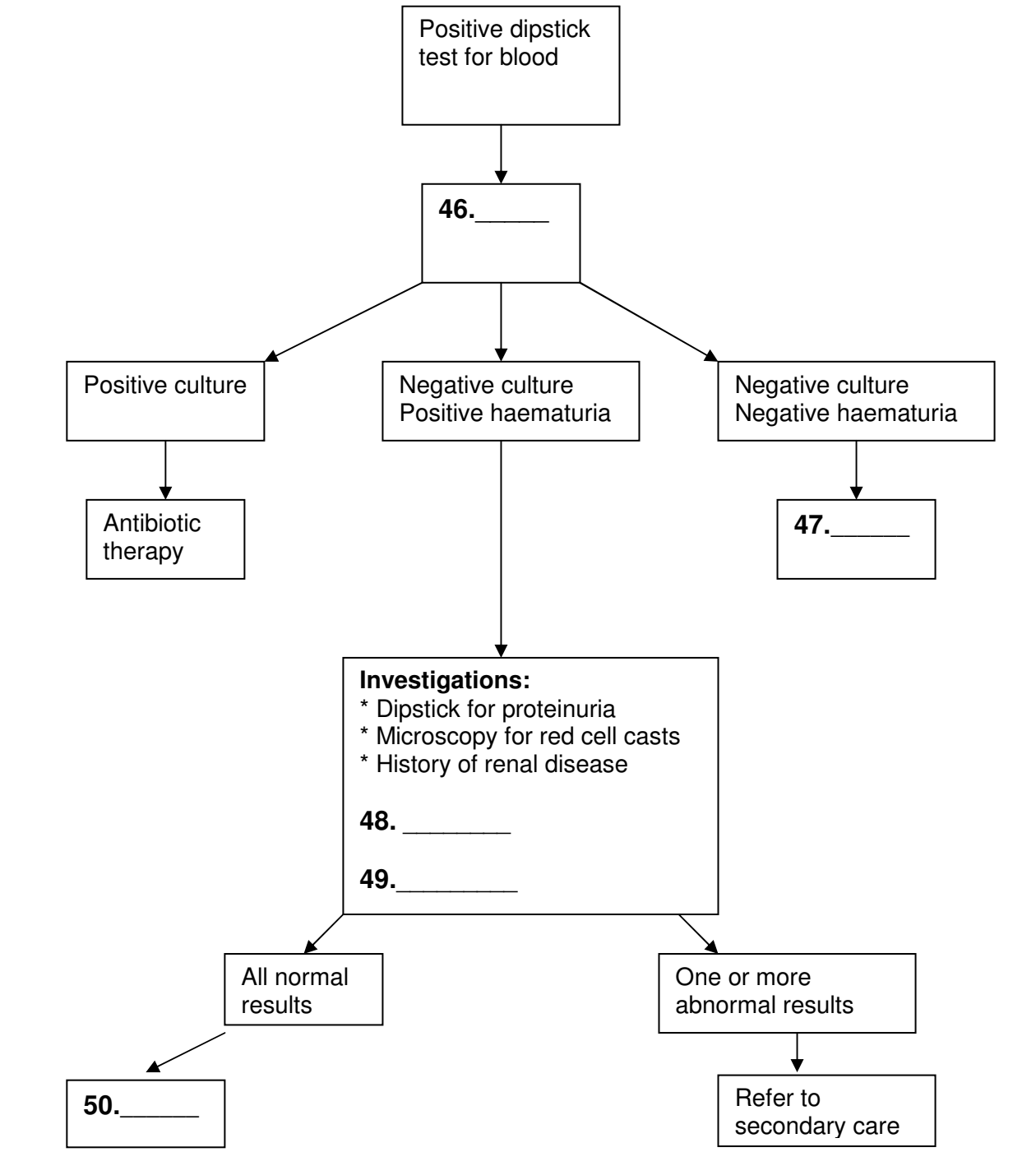
45. Back pain

A 70-year-old woman attends for her repeat prescription of 100 mcg levothyroxine daily, which she has been taking for the past 30 years. The last record of any blood test was six years ago. She mentions a recent episode of quite severe localised back pain which has now settled to a dull ache around the L3 region. She has no neurological signs

Which is the SINGLE MOST likely diagnosis? Select ONE option only.

- A Degenerative disc disease
- B Osteomalacia
- C Osteomyelitis
- D Osteoporosis
- E Paget's disease

Investigation of microscopic haematuria in adults



In the algorithm to investigate asymptomatic microscopic haematuria, complete the numbered gaps with the SINGLE MOST appropriate option from the list below. Each option may be used once, more than once or not at all.

- A Blood pressure
- B Dipstick for glucose
- C Dipstick for microalbuminuria
- D Intravenous urogram
- E No further investigation
- F Serum creatinine
- G Ultrasound scan of renal tract
- H Urine microscopy and culture
- I 24-hour urinary creatinine
- J 24-hour urinary protein